

Pulmonology: Bronchoscopy Procedure Note Sample

Patient Name:	Doe, Jane	MRN:	63344634726
Date of Birth:	12/13/1963	Admit Type:	Outpatient
Age:	49	Room:	Pulm
Gender:	Male	Procedure Date:	6/26/2013

Providers: Unknown . Johnson, MD

Referring MD: Known Smith, MD

Exam Type: Bronchoscopy

Indications: Left lower lobe mass, Hemoptysis, Hilar lymphadenopathy of the left side

Medicines: Midazolam 2 mg IV, Fentanyl 100 mcg IV, Atropine/Lidocaine 4% nebulizer 0.5 mg

Complications: No immediate complications

Procedure: Pre-Anesthesia Assessment:

A History and Physical has been performed. Patient meds and allergies have been reviewed. The risks and benefits of the procedure and the sedation options and risks were discussed with the patient. All questions were answered and informed consent was obtained. Patient identification and proposed procedure were verified prior to the procedure by the physician, the nurse and the anesthesiologist in the pre-procedure area. Mental Status Examination: normal. Airway Examination: normal oropharyngeal airway. Respiratory Examination: clear to auscultation. CV Examination: normal. ASA Grade Assessment: II - A patient with mild systemic disease. After reviewing the risks and benefits, the patient was deemed in satisfactory condition to undergo the procedure. The anesthesia plan was to use moderate sedation / analgesia (conscious sedation). Immediately prior to administration of medications, the patient was re-assessed for adequacy to receive sedatives. The heart rate, respiratory rate, oxygen saturations, blood pressure, adequacy of pulmonary ventilation, and response to care were monitored throughout the procedure. The physical status of the patient was re-assessed after the procedure.

After obtaining informed consent, the bronchoscope was introduced through the right nostril and advanced to the tracheobronchial tree of both lungs. The procedure was accomplished without difficulty. The patient tolerated the procedure well.

Findings:

The nasopharynx/oropharynx appears normal. The larynx appears normal. The vocal cords are normal and move normally with phonation and breathing. The subglottic space is normal. The trachea is of normal caliber. The carina is sharp. The tracheobronchial tree of the right lung was examined to at least the first subsegmental level. Bronchial mucosa and anatomy in the right lung are normal; there are no endobronchial lesions, and no secretions.

Left Lung Abnormalities: A partially obstructing mass was found 2 cm from the bifurcation (carina) in the left lower lobe. The mass was medium-sized and bloody, friable and fungating. The lesion was successfully traversed.

Endobronchial biopsies were performed in the left lower lobe of the lung using a forceps and sent for cell count, cytology, bacterial culture, viral smears & culture, and fungal and AFB analysis. Two samples were obtained.

Estimated blood loss: 10 mL, which was treated with electrocautery.

Patient Name:	Doe, Jane	MRN:	63344634726
Date of Birth:	12/13/1963	Admit Type:	Outpatient
Age:	49	Room:	Pulm
Gender:	Male	Procedure Date:	6/26/2013

Impression:

- Hemoptysis
- Hilar lymphadenopathy of the left side
- The right lung was normal.
- A bloody, friable and fungating mass was found in the left lower lobe. This lesion is likely malignant.
- An endobronchial biopsy was performed.

Recommendation:

- Await test results.
- Refer to/consult with Thoracic Surgery.

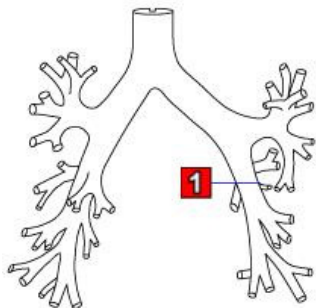
Procedure Code(s): --- Professional ---
31625, Bronchoscopy, rigid or flexible, including fluoroscopic guidance, when performed; with bronchial or endobronchial biopsy(s), single or multiple sites

Diagnosis Code(s): --- Professional ---
786.30, Hemoptysis, unspecified
785.6, Enlargement of lymph nodes
518.89, Other diseases of lung, not elsewhere classified
793.19, Other nonspecific abnormal finding of lung field

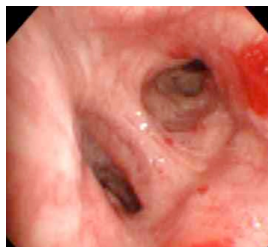
CPT © 2012 American Medical Association. All Rights Reserved.

The codes documented in this report are preliminary and upon coder review may be revised to meet current compliance requirements.

Procedure Images:



Tracheobronchial Tree



1 Left lower lobe

Dr. Sample Signature

Unknown Johnson, MD
6/26/2013 1:43:12 PM

This report has been signed electronically.

Printed 2013. Codes subject to change based on quarterly/annual CPT/ICD/CCI changes.